

Northern Ireland Disease Surveillance Report, JANUARY to MARCH 2015

- Urea toxicity in a cow
- Sporadic bovine lymphoma in a heifer
- Listerial encephalitis in a cow
- Pneumonia in sheep
- *Streptococcus suis* infection in pigs
- Cold stunning in a loggerhead turtle

These are some of the matters discussed in the Northern Ireland animal disease surveillance quarterly report for January to March 2015

CATTLE:

Respiratory diseases

Respiratory disease was identified in 72 cattle post mortem submissions between January and March 2015. The most common pathogens identified included *Mycoplasma bovis* (twenty eight cases), *Mannheimia haemolytica* (seventeen cases), *Pasteurella multocida* (sixteen cases) and *Trueperella pyogenes* (eight cases).

Alimentary diseases

Of 2,565 blood samples that were tested for bovine viral diarrhoea virus (BVDV) by virus isolation or antigen capture ELISA 260 (10.1 per cent) were positive. In addition, 5 of 272 (1.8 per cent) submitted tissues and nasal mucus samples were positive by immunofluorescence. Two cases of mucosal disease were confirmed at post mortem examination during this period.

Cryptosporidiosis, rotavirus infection and colisepticaemia due to infection with an *E. coli* ESBL positive serotype were diagnosed as the causes of an outbreak of enteritis and septicaemia in a group of neonatal dairy calves. Deaths occurred at around three days of age and it was noted that uptake of colostral antibody had been inadequate on the basis of zinc sulphate turbidity test results.

Neonatal enteritis

The pathogens identified in neonatal bovine faecal samples during the quarter are shown in TABLE 1. Overall, *Cryptosporidium* species and rotavirus were the most common pathogens identified.

TABLE 1: Pathogens identified in neonatal bovine faecal samples in Northern Ireland, January to March 2015

Pathogen	Number	
	Tested	Positive (per cent)
<i>Cryptosporidium</i> species	542	177 (32.6%)
Rotavirus	524	162 (30.9%)
Coronavirus	534	31 (5.8%)
<i>Escherichia coli</i> K99	229	3 (1.3%)

Other enteric conditions

Parasitic ova found in ruminant faeces samples submitted during the period are shown in TABLE 2.

TABLE 2: Endoparasitic infections in ruminants in Northern Ireland, January to March 2015

	Total	No of parasitic ova					% positive
		Negative	+	++	+++	++++	
Liver fluke							
Bovine	621	540	65	16	0	0	13.0%
Ovine	217	160	21	19	8	9	26.3%
Paramphistome							
Bovine	639	286	128	137	54	34	55.2%
Ovine	217	141	34	27	13	2	35.0%
Coccidia							
Bovine	747	670	55	13	5	4	10.3%
Ovine	259	153	83	5	4	14	40.9%
Strongyle worm egg count	Total	<500 epg	≥500 epg		% Positive		
Bovine	713	697	16		2.2%		
Ovine	249	197	52		20.9%		

≥500 eggs per gram of faeces (epg) was considered of likely clinical significance
+ Low, ++ Moderate, +++ High, ++++ Very high

Johne's disease

Examination for *Mycobacterium avium* subspecies *paratuberculosis* (MAP) was carried out by microscopic examination, with Ziehl-Neelsen staining, on 99 bovine faecal samples. Two samples (2.0 per cent) contained acid-fast organisms typical of MAP. Of 9414 bovine blood samples that were tested for antibodies to MAP 686 (9.3 per cent) were positive.

Nutritional and metabolic disease

Urea toxicity

Urea toxicity was diagnosed in a three-year-old cow which had gained access to urea pellets by dislodging a wooden pallet behind which a bag of pellets had been stored. Clinical signs included sclera haemorrhage, generalised congestion and bloating with froth and fresh blood being present at the nostrils. Three animals in total were affected and all died. On gross post-mortem examination there were a large number of pellets present in the rumen and the rumen contents smelt strongly of ammonia, the rumen pH was 9.0 which is consistent with urea toxicity.

Copper toxicity

Yellow-brown colouration of serosa and connective tissue with widespread echymoses were the principle findings on post-mortem examination of a three-month-old heifer that had died suddenly. Histologically there was severe hepatic necrosis. Liver copper levels were high (170 µg/g wet weight) whilst the kidney copper was at a level consistent with copper toxicity (31 µg/g wet weight). Advice was given to review the copper intake of the group of calves.

Reproductive and mammary diseases

Abortion

Specimens from 134 bovine abortions and stillbirths were examined during the 1st quarter. Significant pathogens were detected in 66 cases (49.3 per cent). Of these, *Bacillus licheniformis* (19 cases, 14.2 per cent) was the most commonly identified pathogen. Other pathogens identified included *T. pyogenes* (15 cases, 11.2 per cent),

Neospora caninum (14 cases, 10.4 per cent), leptospiral infection (9 cases, 6.7 per cent) and *E. coli* (4 cases, 3.0 per cent).

Mastitis

A total of 266 bacterial isolates were cultured from milk samples submitted from acute and chronic mastitis cases. 19 (7.1 per cent) samples yielded cultures of more than two organisms and were considered to be potentially contaminated. No bacteria were cultured in a further 69 samples. *Streptococcus uberis* was the most frequently isolated organism and accounted for 15.4 per cent of isolates cultured.

Other frequently identified organisms included, *E. coli* (13.9 per cent), *Staphylococcus aureus* (12.8 per cent), *Streptococcus dysgalactiae* (6.4 per cent), coagulase negative *Staphylococcus* species (6.0 per cent), and *B. lichenformis* (3.8 per cent).

Neurological diseases

Clostridium botulinum type C / D toxicosis was diagnosed in 5 cases during the 1st quarter of 2015 including one case in an adult dairy cow, housed indoors and being fed silage. In this case there was intercurrent chronic fasciolosis. The cow had presented with hypothermia, foreleg weakness and paddling.

Listerial encephalitis, intercurrent chronic fasciolosis and bacterial pneumonia were diagnosed in a seventeen-month-old heifer which had been presented for examination as a suspect case of botulism. Histological examination of the midbrain showed perivascular cuffing with lymphocytes and neutrophils; there was an associated microgliosis with oedema of the neuropil (FIGURE 1). There was fibrinous lobar pneumonia present with expansion of the interlobular septae with fibrin, expansion of the alveolar walls with lymphocytes and neutrophils and leucocytic aggregation in the airspaces with associated pneumocyte necrosis.

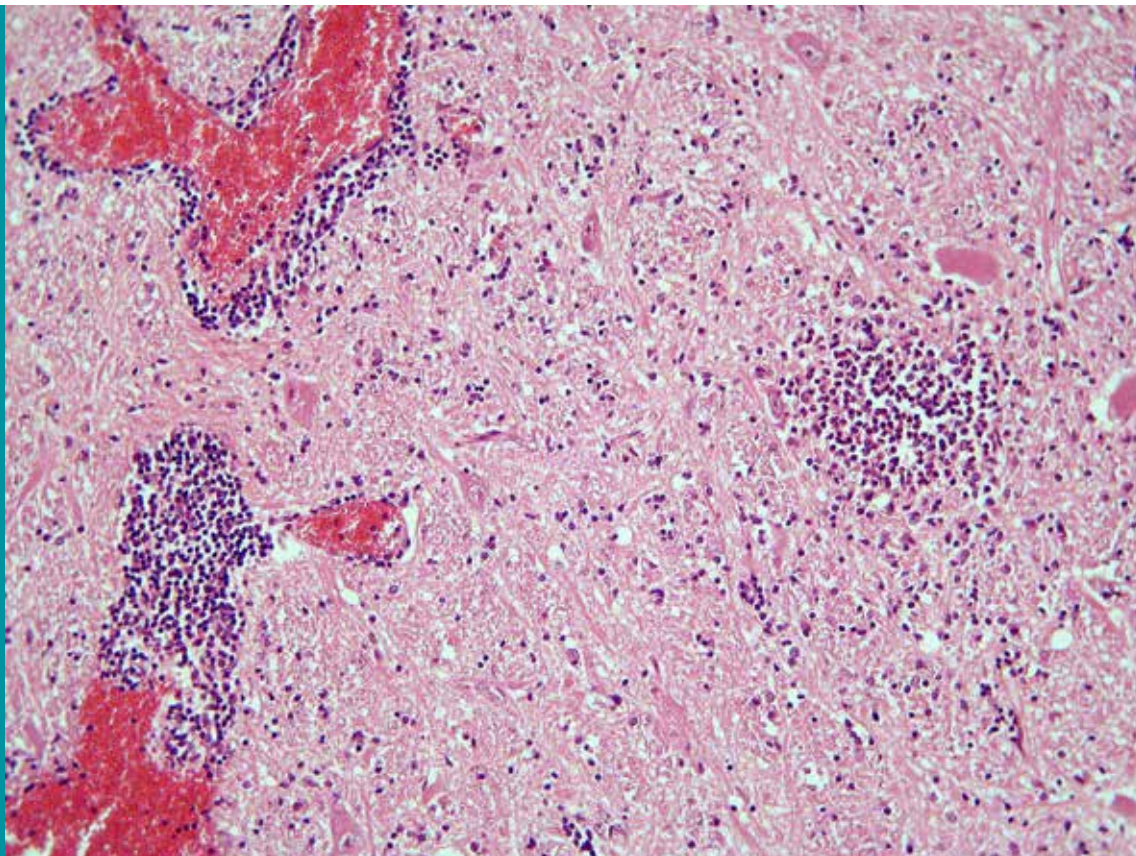


Figure 1

Listerial encephalitis, perivascular cuffing, focal microgliosis and neuropil oedema can clearly be seen

Other diseases of cattle

Sporadic lymphoma in a heifer

Bovine lymphoma was diagnosed on the basis of gross and histological findings in a one-year-old heifer which presented unable to rise. On gross examination carcass lymph nodes were very prominent and the liver was swollen and pale. Histologically there was a heavy lymphoid infiltrate in the liver and lymph nodes with more moderate infiltration of the kidney and mild perivascular lymphoid cuffing in the brain and spinal cord. Serology for enzootic bovine leucosis (EBL) was negative.

The so-called sporadic types of bovine lymphoma are not associated with retrovirus (bovine leukaemia virus / BLV) infection and are classically described as being of the calf or juvenile form, the thymic form, the adult form or the cutaneous form of the disease. Sporadic bovine lymphomas are associated with a T- cell lineage and this is in contrast to B-cell line tumours resulting from BLV infection.

SMALL RUMINANTS: SHEEP

Respiratory diseases

Respiratory disease was identified in 27 ovine post mortem submissions during this quarter. Jaagsiekte (fifteen cases), *M. haemolytica* (eight cases) and necrotising laryngitis (two cases) were the most common diagnoses. In one instance *Mannheimia glucosida* was recovered from the lung of a six-week-old lamb with suppurative bronchopneumonia. *M. glucosida* is proposed to include [*P.*] *haemolytica* serovar 11, biogroups 3A-H and the β -glucosidase and meso-inositol positive strains of biogroup 9 and is considered to be an opportunistic pathogen in sheep.

Pneumonia in sheep may have a complex aetiology (FIGURE 2) and any investigation of flock problems should also take into account not only common respiratory pathogens but also any inter-current disease and management factors.

The Pneumonia Complex in Sheep

Pneumonic pasteurellosis

Mannheimia haemolytica

Viral pneumonia

P13, RSV, adenovirus, reovirus

Mycoplasmal (atypical) pneumonia

Mycoplasma ovipneumoniae

Other Specific Causes

Jaagsiekte (OPA, SPA), Lungworm, Maedi

Figure 2

Respiratory pathogens in sheep, which frequently occur in combination to cause pneumonia in a flock

Alimentary diseases

Johne's disease

7 ovine faecal samples were examined microscopically using Ziehl-Neelsen staining for MAP. No samples contained acid-fast organisms typical of MAP. Of 8 ovine blood samples that were tested for antibodies to MAP 1 (12.1 per cent) were positive.

Hernia in a heavily pregnant ewe

A two-year-old ewe died with a history of frothing at the mouth. On gross post-mortem examination the carcass was ketotic and the urine gave a positive result on the Rothera's test for ketone bodies. There were two large term lambs present in the uterus. A diaphragmatic hernia was present and the entire small and large intestine had herniated into the thoracic cavity. Congestion of the blood vessels in the mesentery and engorgement of the vessels on the cranial aspect of the diaphragm indicated that this was an ante mortem event probably precipitated by abdominal overfill in a heavily pregnant ewe.

Reproductive diseases

Abortion

Specimens from 175 ovine abortions and stillbirths were examined during the 1st quarter of 2015. Significant pathogens were detected in 114 cases (65.1 per cent). Pathogens identified included *Toxoplasma gondii* (45 cases, 25.7 per cent), *Chlamydophilia abortus* (35 cases, 20.0 per cent), *E. coli* (10 cases, 5.7 per cent), *Listeria* species (7 cases, 4.0 per cent), *Campylobacter* species (5 cases, 2.9 per cent) and leptospiral infection (5 cases, 2.9 per cent).

Yersinia pseudotuberculosis was recovered in pure culture from the foetal stomach contents (FSC) of an ovine foetus submitted in February. *Y. pseudotuberculosis* has been reported as a cause of abortion and purulent placentitis in sheep, but is rarely identified as a cause of abortion in sheep in Northern Ireland. Good nutrition and the avoidance of stress are important in preventing disease.

Neurological diseases

No cases of listerial encephalitis in sheep were confirmed by post-mortem examination during the 1st quarter of 2015.

A ram died after fighting with another ram and was found to have a lepto-meningeal haematoma on gross post-mortem examination. There was mild haemorrhage into the sinus of the frontal bone and significant haemorrhage into the lepto-meninges around the brainstem (FIGURE 3). The changes were considered consistent with contrecoup injury which can be produced by fighting in rams.

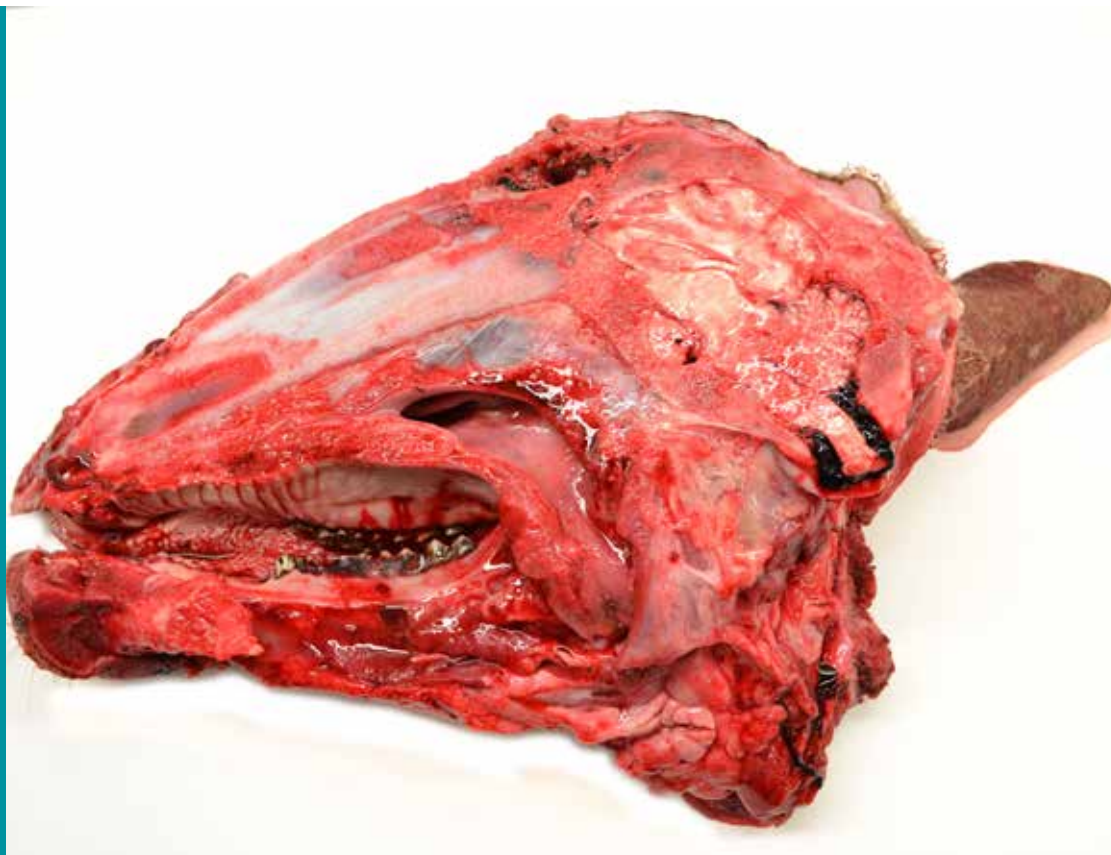

Figure 3

Contrecoup injury in a ram: the frontal sinus (coup) and lepto-meningeal haemorrhage (contrecoup) lesions are both visible

Skin diseases

No cases were examined for sheep scab during the 1st quarter of 2015

Musculoskeletal diseases

Septicaemia and septic arthritis due to *Streptococcus dysgalactiae* infection was diagnosed in young lambs in an indoor lambing flock. Advice was given on lambing pen hygiene and prompt treatment of navels. In another flock with similar problems, BVDV antigen was detected by ELISA in the abomasum, mesenteric lymph node and spleen of a young lamb submitted for necropsy. Advice was given to further investigate the BVDV infection in this flock in the light of the association of this virus with Border Disease in sheep.

HORSES:

159 swabs were examined for the presence of *Tayorella equigenitalis* during this quarter, all of which were negative. Two swabs were cultured from horses with a history suggestive of strangles during this quarter, one of which was negative.

Abortion due to equine herpesvirus

Three aborted foals from the same herd were examined in late March. There were carcass haemorrhages, straw coloured pleural effusion, pulmonary petechiae and abdominal oedema on gross examination. Histologically there was necrotic hepatitis and splenitis in each foal with intranuclear inclusion bodies in the liver of one. Gross and histological findings were suggestive of equid viral abortion (due to equine herpesvirus). EHV antigen was detected in foetal liver of each foal by immunofluorescence.

PIGS;

Meningitis due to *Streptococcus suis* infection was diagnosed in growing pigs in two herds during the reporting period. Cultures were retained for autogenous vaccine production in one herd.

WILDLIFE and EXOTICS:

Hypothermia, usually referred to as 'cold stunning' was diagnosed in a juvenile loggerhead turtle (*Caretta caretta*) which had washed up on the Northwest coast of Ireland (FIGURE 4), and died despite attempts at treatment in a marine animal rehabilitation facility. Cold stunning occurs when oceanic turtles reach cold seas in which the water temperature is too low for their temperature regulation, metabolic function and survival. In this case full gross post-mortem examination, histopathology and bacteriology failed to provide evidence of intercurrent disease or other cause of death.



Figure 4

Juvenile loggerhead turtle which died due to cold stunning in the North Atlantic. The five lateral scutes of the carapace which are characteristic of this species can be seen