

Disease Surveillance and Investigation Branch

DISEASE SURVEILLANCE REPORT

Northern Ireland Disease Surveillance Report, July to September 2017

- Abortion due to *Streptococcus pluranimalium* in cattle
- Lymphoma in cattle
- Brassica poisoning in sheep
- Acute fasciolosis in sheep
- Marek's disease in chickens
- Erysipelas in pigs

These are some of the matters discussed in the Northern Ireland animal disease surveillance quarterly report for July to September 2017

CATTLE:

Respiratory diseases

Respiratory disease was identified in 52 cattle post mortem submissions between July and September 2017. The most common pathogens identified included:

- *Dictyocaulus viviparus* (eighteen cases),
- *Mycoplasma bovis* (eleven cases),
- *Pasteurella multocida* (eight cases),
- *Mannheimia haemolytica* (four cases)
- *Trueperella pyogenes* (three cases) and
- bovine RSV (three cases).

Pulmonary abscessation in a bullock

Pulmonary abscessation with erosion of the diaphragm was diagnosed in a two-year-old bullock which had been found recumbent in the field. On gross examination there were scattered cords of fibrous adhesions between lung and the thoracic wall. There was consolidation of the left middle lobe and an area of walled off pus in the caudal portions of the right diaphragmatic lobe. The pus filled cavity in the right diaphragmatic lobe was continuous through a circular defect (8cm in diameter) in the diaphragm and was contained within a pocket between diaphragm and liver capsule.

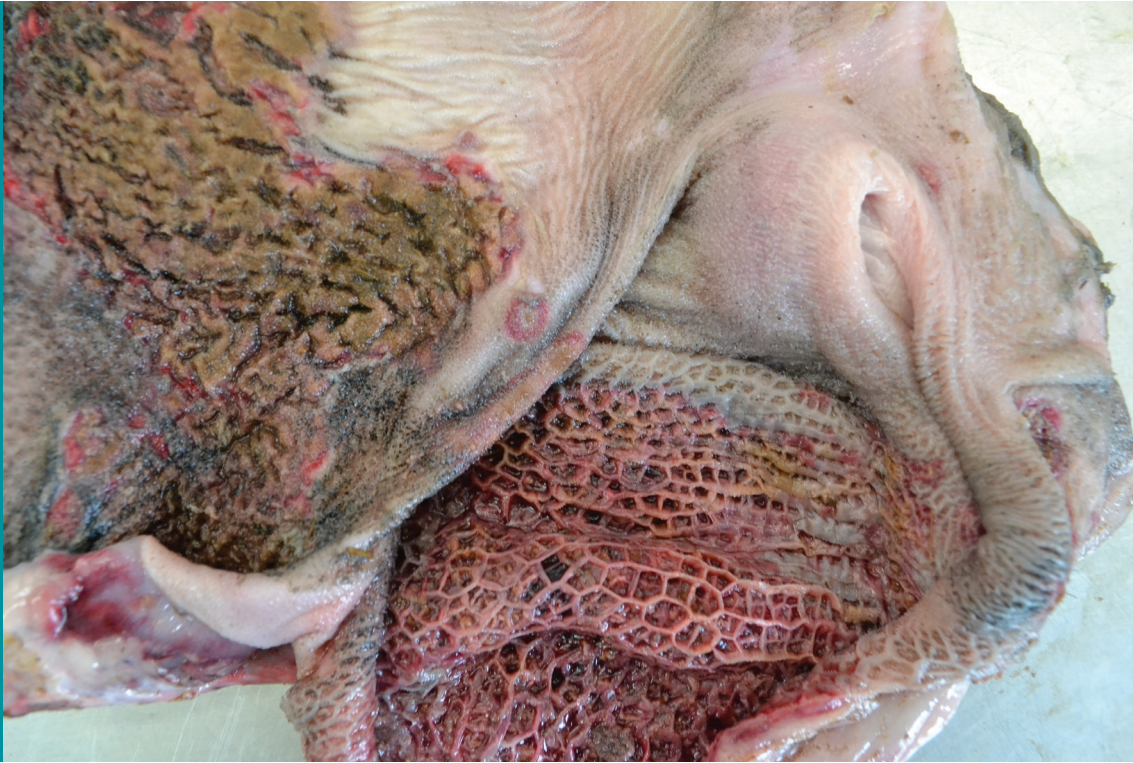Alimentary diseases

CASE 018395 VRO RH

Adynamic (paralytic) ileus was diagnosed in a five-day-old calf. At gross post mortem examination the caecum and colon were found to be distended with semi-solid, yellow content and meconium. The wall of the caecum was devitalised and perforated in patches with fibrin attached to the serosal surface. The anus was perforate in this case.

CASE 015216 VRO SF

Mycotic gastroenteritis was diagnosed in a three-month-old calf with severe inflammatory lesions in the rumen, reticulum, abomasum and small intestine (FIGURE 1). Much of the rumen and reticular walls were red/black and thickened. The mucosa was bright red to red/black or black and large parts of the serosa were red/black. The coloured mucosa was thickened, rough and sometimes eroded. There were numerous smaller circular mucosal erosions. *Candida* sp was recovered in profuse growth from the rumen and abomasum.

**Figure 1**

Mycotic gastroenteritis in a calf, *Candida* sp were recovered from the lesions

Neonatal enteritis

The pathogens identified in neonatal bovine faecal samples during the quarter are shown in TABLE 1. Overall, *Cryptosporidium* species and Rotavirus were the most common pathogens identified.

TABLE 1: Pathogens identified in neonatal bovine faecal samples in Northern Ireland, July to September 2017

Pathogen	Number	
	Tested	Positive (per cent)
<i>Cryptosporidium</i> species	100	23 (23.0%)
Rotavirus	98	22 (22.4%)
Coronavirus	98	4 (4.1%)
<i>Escherichia coli</i> K99	71	4 (5.6%)

Other enteric conditions

Parasitic ova found in ruminant faeces samples submitted during the period are shown in TABLE 2 on page 3

TABLE 2: Endoparasitic infections in ruminants in Northern Ireland, July to September 2017

	Total	No of parasitic ova					% positive
		Negative	+	++	+++	++++	
Liver fluke							
Bovine	781	727	51	3	0	0	6.9%
Ovine	508	474	26	8	0	0	6.7%
Paramphistome							
Bovine	781	437	62	154	49	79	44.0%
Ovine	508	485	22	34	12	5	14.4%
Coccidia							
Bovine	822	530	262	20	4	6	35.5%
Ovine	513	96	325	72	17	3	81.3%
Strongyle worm egg count							
	Total	<500 epg	≥500 epg				% Positive
Bovine	816	762	54				6.6%
Ovine	511	389	122				23.9%

≥500 eggs per gram of faeces (epg) was considered of likely clinical significance
 + Low, ++ Moderate, +++ High, ++++ Very high

Johne's disease

Examination for *Mycobacterium avium* subspecies *paratuberculosis* (MAP) was carried out by microscopic examination, with Ziehl-Neelsen staining, on 137 bovine faecal samples. 32 samples (23.4 per cent) contained acid-fast organisms typical of MAP. Of 2089 bovine blood samples that were tested for antibodies to MAP 230, (1.3 per cent) were positive.

Nutritional and metabolic disease

CASE 019680 VRO SF

A vitreous humour magnesium level of 0.3 mM/l was detected in a cow which died suddenly, the second sudden cow death in the herd in two weeks. Vitreous humour magnesium levels less than 0.55 Mm/l in fresh dead cows are considered consistent with hypomagnesaemia. The cow was fat and there was also mild to moderate fatty liver.

Reproductive and mammary diseases

Abortion

Specimens from 97 bovine abortions and stillbirths were examined during the 3rd quarter. Significant pathogens were detected in 39 cases (40.2 per cent). Of these, *T. pyogenes* (6 cases, 6.2 per cent) and *Neospora caninum* (6 cases, 6.2 per cent) were the most commonly identified pathogens.

Other pathogens identified included BVD (5 cases, 5.2 per cent), *E. coli* (5 cases, 5.2 per cent) and *Salmonella* Dublin (4 cases, 4.1 per cent).

Abortion due to *Streptococcus pluranimalium*

Abortion due the *Streptococcus pluranimalium* infection was diagnosed in a foetus aborted at around eight month's gestation. Histopathology of the lung showed extensive foetal bronchopneumonia with fibrin and a large number of granulocytes and macrophages, including occasional multinucleate cells within alveoli and airways. *Strep. pluranimalium* was recovered in profuse pure growth from the foetal stomach contents.

Mastitis

A total of 295 bacterial isolates were cultured from milk samples submitted from acute and chronic mastitis cases. 41 (13.9 per cent) samples yielded cultures of more than two organisms and were considered to be potentially contaminated. No bacteria were cultured in a further 18 samples. *E. coli* was the most frequently isolated organism and accounted for 24.4 per cent of isolates cultured. Other frequently identified organisms included, *Streptococcus uberis* (21.7 per cent) and *Staphylococcus aureus* (6.1 per cent).

Neurological diseases

Clostridium botulinum type C/D toxicosis was diagnosed in 3 cases during the 3rd quarter of 2017.

Other diseases of cattle

CASE 014623 VRO RH

Extensive eosinophilic interstitial myocarditis and abscessation was diagnosed on histological examination of a bovine heart submitted from an abattoir. A few scattered sarcocysts were present but no inflammation was associated with these. Although eosinophilic interstitial myocarditis is associated with sarcocystosis, the condition could not be confirmed in this case because of the lack of inflammatory response associated with the few sarcocysts present.

Clostridial myositis (Blackleg)

Cases of clostridial myositis (Blackleg) were diagnosed in first and second season calves from several herds during the reporting period. In all cases a vaccination programme was either not in place or had not been completed prior to onset of the disease problem. It was emphasised that timely vaccination of beef cattle for the prevention of clostridial diseases including Blackleg is very worthwhile.

Hepatic abscessation and vena caval thrombosis

CASES 018888 and 018953 VRO CF

Hepatic abscessation, phlebitis and thrombosis of the posterior vena cava with septic pulmonary thromboembolism were diagnosed in individual cows in two separate herds during the quarter.

Sporadic bovine lymphoma

Two cases of sporadic bovine lymphoma were diagnosed in individual animals in separate herds during the reporting period. It was noted that the so-called sporadic types of bovine lymphoma are not associated with retrovirus (bovine leukaemia virus / BLV) infection and are classically described as being of the calf or juvenile form, the thymic form, the adult form or the cutaneous form of the disease (FIGURE 2).

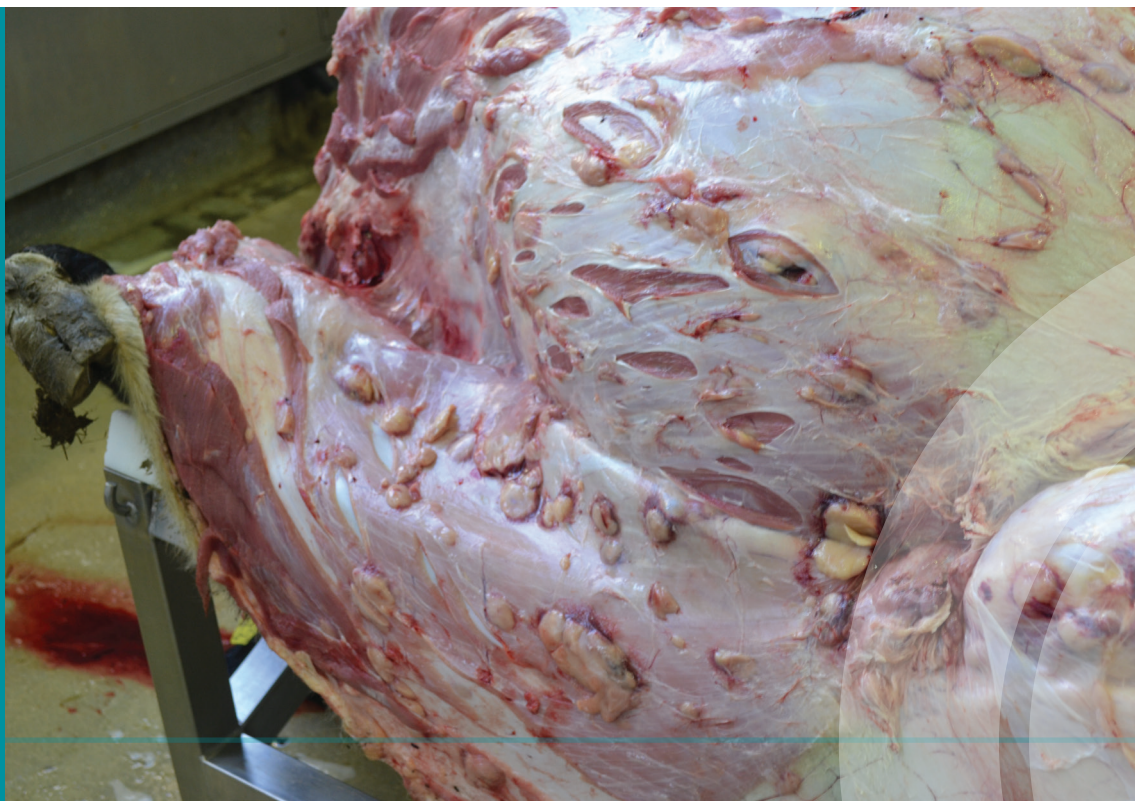

Figure 2
Cutaneous lymphoma in a calf

Dosing gun injury

CASE 018548 VRO CF

A five-year-old cow was submitted having been euthanased on welfare grounds following a period of ill thrift. On gross post mortem examination a large, solid, diffuse mass containing foul smelling liquid pus was detected extending from the ventral mandible to the thoracic inlet. There was associated oesophageal rupture and two intra-ruminal boluses were lodged caudal to the pharynx in a pocket of necrotic tissue

SMALL RUMINANTS: SHEEP

Respiratory diseases

Respiratory disease was identified in 6 ovine post mortem submissions during this quarter. *M. haemolytica* (two cases), laryngeal chondritis (one case) and parasitic pneumonia (one case) were the most common diagnoses.

Alimentary diseases

Incidents of poisoning by rhododendron (*Rhododendron* sp) and forest flame (*Pieris* sp) were noted in two separate flocks during the reporting period. The sheep presented as dull and foaming at the mouth and large numbers of leaves were found amongst the rumen contents in each case. In one instance it was thought that the forest flame had been eaten after wilting following herbicide spraying. In the other it was considered that despite the presence of a large number of rhododendron leaves in the rumen contents, the actual cause of death in the ewe submitted was rupture of the cranial mesenteric artery with catastrophic haemorrhage

Suspected Brassica poisoning

CASE 019726 VRO RH

Brassica poisoning was suspected in a ewe submitted for post mortem examination following sudden death. The findings from the gross and histological examinations were considered to be consistent either with copper toxicity or brassica poisoning. However results of biochemical testing did not support the involvement of copper because liver copper levels were low adequate (20 µg/g) and kidney copper levels were 3.5 µg/g (low marginal). It was considered that icterus, haemoglobinuria and centri-lobular to mid-zonal bridging hepatoparenchymal necrosis could have been due to excess ingestion of brassicas in this case.

Intussusception in ewes

CASES 014397 and 018095 VROs RH and SC

Two instances of intussusception in ewes occurred in two different flocks during the reporting period. Such cases are noted occasionally amongst sheep submitted for post mortem examination and appear to be sporadic in occurrence.

Johne's disease

Twelve ovine faecal samples were examined microscopically using Ziehl-Neelsen staining for MAP. One sample (8.3per cent) contained acid-fast organisms typical of MAP. 5 ovine bloods samples were tested for antibodies to MAP during this quarter, two (40 per cent) of which were positive.

Acute fasciolosis in lambs

CASE 019647 VRO SF

Acute fasciolosis was diagnosed in four-month-old lambs in September, fasciolosis is seen more frequently in the late summer / early autumn than used to be the case in Northern Ireland. It was noted that the pattern of disease was consistent with the AFBI Liver Fluke forecast for 2017/18 which gives warning of a high risk of fasciolosis in sheep flocks over the autumn – winter period.

Reproductive diseases

Abortion

No specimens from ovine abortions and stillbirths were examined during the 3rd quarter of 2017.

Neurological diseases

No cases of listerial encephalitis were confirmed by post mortem examination during the 3rd quarter

Cerebrocortical necrosis (CCN)

CASES 014616 and 017964 VRO RH

Cases of CCN were diagnosed by histopathology in lambs from two flocks during the reporting period, in each case there was intercurrent intestinal parasitism.

Skin diseases

No cases were examined for sheep scab during the 3rd quarter of 2017.

Other diseases

CASE 019636 VRO SF

Towards the end of the quarter, septicaemic pasteurellosis (FIGURE 3) was diagnosed in unvaccinated lambs. Post mortem examination showed necrotic lesions in the tonsils, pharynx and oesophagus in all cases and *Bibersteinia trehalosi* was recovered in septicaemic distribution. It was noted that in each case there was significant intercurrent parasitic gastroenteritis (PGE) demonstrating not only the importance of full and correct vaccination but also the need for adequate anthelmintic programmes to help to control this disease.

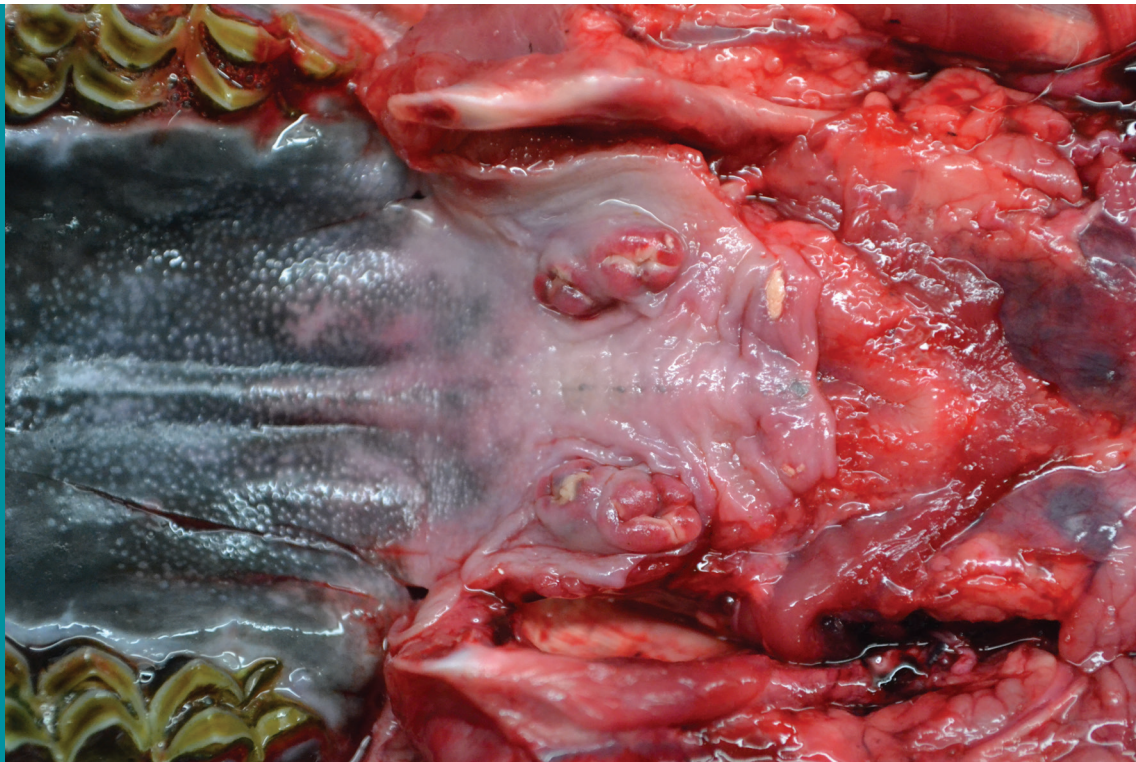


Figure 3

Lymphoid tissue necrosis in a lamb with septicaemic pasteurellosis

HORSES:

3 swabs were examined for the presence of *Tayorella equigenitalis* during this quarter, all were negative. 19 swabs were cultured from horses with a history suggestive of strangles during this quarter, all swabs were negative.

PIGS;

CASE 018714 VRO SF

Three eight-week-old pigs were submitted after sudden death. Two of the carcasses appeared jaundiced and there were rhomboid urticarial lesions in the skin of one pig. *Erysipelothrix rhusiopathiae* was recovered in septicaemic distribution from routine cultures in two of the pigs

BIRDS: Poultry

The diagnostic analysis for poultry post mortem submissions during the quarter is given in CHART 1 on page 7.

POULTRY SUBMISSION DIAGNOSTIC ANALYSIS Q3 2017

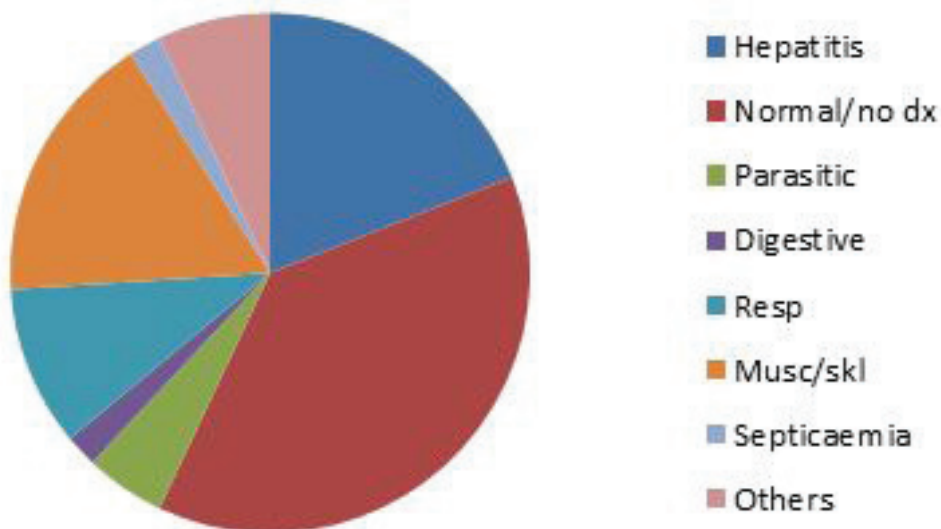


Chart 1

Poultry
Diagnostic
Submission
Analysis,
(Q3 2017)

Liver disease including fatty liver (eight cases, 19.0 %), musculo-skeletal disorders including tendonitis and tendon rupture (seven cases, 17.0% %) and respiratory disease including mycotic pneumonia and air-sacculitis (four cases, 10%) predominated.

CASE 014700 VRO RH

Marek's disease was diagnosed in ten-week-old layer pullets with leg paralysis. In most sciatic nerves examined there were numerous lymphocyte-type cells scattered individually amongst the axons, with occasional small accumulations of lymphocytes throughout the nerve fibre, foci of lymphocytes were seen in the epineurium and around the associated blood capillaries.

BIRDS: Cage and aviary

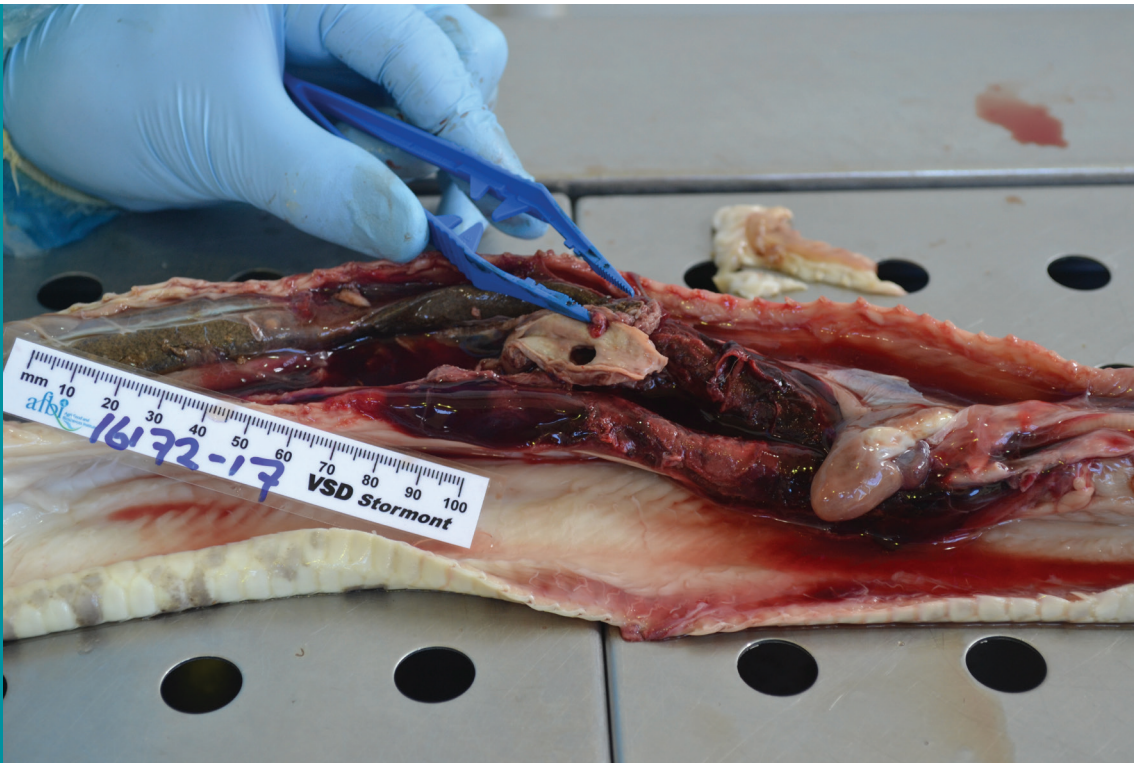CASE 019622 VRO SF

Very heavy *Capillaria* infections were diagnosed in two young ill thrifty pigeons. In both birds, approximately 20,000 *Capillaria* eggs were detected per gram of faeces. Other post mortem findings were unremarkable.

WILDLIFE and EXOTICS:

CASE 016172 VRO RH

Bacterial endarteritis and consequent aortic aneurism were diagnosed in a four-year-old female Royal Python submitted from a zoological collection. On gross examination the middle region of the body cavity caudal to the heart was occupied by a large blood clot adherent to the wall of the dorsal aorta and associated with a rupture of the artery wall (FIGURE 4 on page 8). The liver was enlarged with green-yellow discolouration and multiple pale foci were present in the parenchyma. Histological examination showed severe acute endarteritis featuring numerous large heterophils and less conspicuous lymphocytes. In some areas there was haemorrhagic dissection of the layers of the artery wall, associated with aneurism. Throughout the affected tissue there were circumscribed colonies of bacteria. A group S *Salmonella* with somatic antigen formula O-41 but not expressing H (flagellar) antigen in either phase 1 or phase 2 was recovered from the stomach lining and necrotic arterial tissue.

**Figure 4**

Aneurysm and arterial rupture with haemorrhage in a Royal Python