



## Northern Ireland Disease Surveillance Report, April to June 2022

- Pneumonia due to Infectious Bovine Rhinotracheitis (IBR) in calves
- Pneumonia due to *Mycoplasma bovis* in calves
- Poisoning due to lead in cattle
- Nematodirosis in lambs
- Johne's disease in a ram
- Goitre in lambs

These are some of the matters discussed in the Northern Ireland animal disease surveillance quarterly report for April to June 2022

## CATTLE:

### Respiratory diseases

Two cases of pneumonia and severe tracheitis (FIGURE 1) were diagnosed in heifers from different herds during the reporting period. On gross examination there was a massive purulent tracheitis with pseudo-diphtheritic membrane formation and extensive oedema of the laryngeal region. The apical, cardiac and middle lung lobes were hyperaemic and consolidated with around 30% of the total lung field being affected in each case. Histologically, there was severe fibrino-necrotic bronchopneumonia with ring-lesions and toxic modification of neutrophils; marked septal oedema and bacterial colonisation (small rods). In the trachea there was severe acute tracheitis with loss of tracheal epithelium, fibrino-necrotic diphtheresis and bacterial colonisation. RT-PCR and immunofluorescence (IFAT) detected presence of IBRv nucleic acid and antigen respectively in the lung and the virus was isolated from lung tissue. *Mannheimia haemolytica* was present as a secondary pathogen and this is not unusual in these cases.

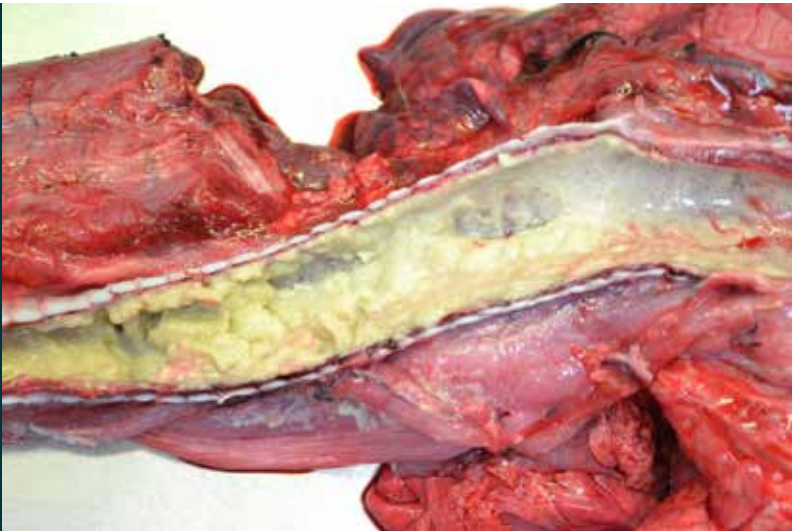

FIGURE 1: Severe tracheitis in a heifer, due to IBR.

### Pneumonia due to *Mycoplasma bovis* infection

Incidences of pneumonia in calves due to *Mycoplasma bovis* infection were recorded on several occasions during the quarter. In one case there was intercurrent infection with *Bibersteinia trehalosi* which has been documented as a cause of acute pneumonia in calves.

At necropsy, lesions of pneumonia were present with tracheitis and deep-purple consolidation of the apical, middle and cardiac lobes, with around 40% of the lung field affected. There were emphysematous bullae in the caudal lobes and there was fibrinous expansion of the interlobular septae. Histologically there was fibrinous bronchopneumonia with focal caseous parenchymal necrosis with lesions bordered by degenerating leucocytes, expansion of the alveolar walls with neutrophils and lymphocytes and leucocytic aggregation in the airspaces. Inflammatory exudate was present in the airways and there was hydropic change and necrosis of the bronchiolar epithelium. *Mycoplasma bovis* nucleic acid was detected in lung tissue by RT-PCR.

## Alimentary diseases

### Johne's disease

439 sera were tested for MAP antibody during the reporting period, of these one hundred and eighteen were positive. 480 faeces samples were tested for presence of MAP nucleic acid by RT-PCR, of these eighty two were positive.

## Nutritional and metabolic disease

### Lead poisoning

Poisoning due to lead was diagnosed in an eight-month-old calf which died within twelve hours of developing blindness. A previous calf in this cohort had also died following onset of blindness. Gross post mortem findings were unremarkable but a high level of lead was detected in the kidney (89.9 ug/g wet tissue).

Another case of lead poisoning in a separate herd involved an adult cow; again gross findings were unremarkable but elevated levels of lead were detected in the blood, liver and kidney.

### Ragwort poisoning

Pyrrolizidine alkaloid toxicity following ingestion of ragwort (*Senecio jacobaea*) was diagnosed in a seven-year-old dairy cow submitted with a history of flaccid paralysis twenty four hours prior to death. This was the sixth such cow to die and botulism was suspected on the basis of clinical examination but was not confirmed by detection of *Clostridium botulinum* toxins by ELISA. Histopathology of the liver revealed widespread portal fibrosis, bile duct proliferation and megalocytosis. The lesions were considered to be consistent with ragwort poisoning.

### Nutritional cardiomyopathy

A one-week-old calf which died suddenly at pasture was submitted for post mortem examination. At necropsy the epicardial surface of the left ventricle was pale and there were foci (2mm x 3cm) of pallor in the myocardium of the ventricles. Histologically, there was focal-to-more diffuse myocardocyte degeneration and necrosis with presence of swollen hyper-eosinophilic, fragmented myocardiofibrils and an associated macrophage infiltration. The gross and histological lesions were considered to be consistent with nutritional cardiomyopathy.

## Reproductive and mammary diseases

### Abortion

*Trueperella pyogenes* and *Salmonella* Dublin were the most common abortion pathogens detected during the quarter; cases due to *Bacillus licheniformis* infections decreased compared to the first quarter.

Abortion due to BVDv infection was diagnosed in a 16.5 kg foetus in which BVDv nucleic acid was detected in foetal fluid by RT-PCR. Arthrogryposis and hyper-extension of the hind limbs was noted but testing for Schmallenberg virus (SBV) by RT-PCR in foetal tissues and antibody to SBV in foetal fluid was completed with negative results.

## Abortion due to Ureaplasma

Ureaplasma abortion was considered possible in a 6.9 kg foetus in which there was marked hyperplasia of peri-bronchiolar and peri-bronchial lymphoid tissue (FIGURE 2), and marked thickening of inter-alveolar septae by lymphocytic infiltration.

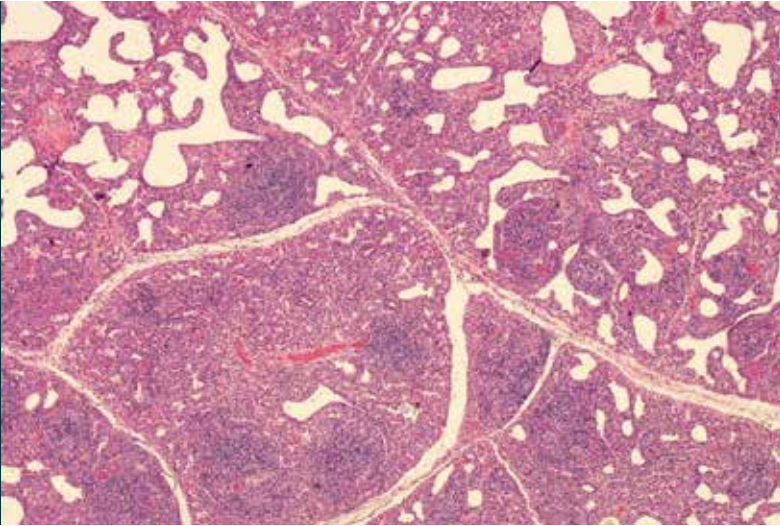


FIGURE 2: Suspected Ureaplasma abortion, characteristic peri-bronchiolar lymphoid hyperplasia can be seen

## Other reproductive diseases

Peritonitis resulting from laceration of the lower reproductive tract was diagnosed in an adult cow which was euthanased on welfare grounds. Gross post-mortem examination revealed severe fibrinous peritonitis. There was a large volume of foetid fluid in the abdomen with multiple visceral adhesions obscuring the normal anatomy. No perforations were found in the gastrointestinal tract, but the uterus was full of yellow fluid and fibrin, and in the distal reproductive tract there was fibrinous diphtheresis and some ulceration. Histologically there was severe necrotising vaginitis affecting the full thickness of the mucosa, with oedema and acute inflammation extending into the muscularis.

## Mastitis

During the reporting period, *E.coli* was the most commonly diagnosed cause of bovine mastitis, followed by *Streptococcus uberis* and *Staphylococcus aureus*.

## Neurological diseases

Cerebrocortical necrosis (CCN) and acidosis was diagnosed in a group of heifers in which six animals had been showing clinical signs consistent with CCN but responding poorly to treatment with vitamin B1, dexamethasone and oxytetracycline. Different cuts of silage had been fed over a short period of time but the level of concentrate feeding had not been changed.

## Other diseases of cattle

### Arthritis and otitis media due to *Mycoplasma bovis* infection

Arthritis and otitis media due to *Mycoplasma bovis* infection was diagnosed in a one-month-old calf. On gross examination there was thick purulent- to- caseous material in the tympanic bullae and



abundant purulent material in most limb joints, causing swelling (marked in the case of the carpal joints). Histology of the joint capsule showed multiple acidophilic foci of caseous necrosis with a rim of degenerating neutrophils, bordered by fibrosis and lymphohistiocytic cells. *Mycoplasma bovis* nucleic acid was detected in carpal joint and tympanic bullae swabs by RT-PCR.

## SMALL RUMINANTS: SHEEP

### Alimentary diseases

#### Enteric disease in young lambs

Cases of enteritis in neonatal and young lambs were investigated in several flocks during the quarter. In very young lambs, *Cryptosporidium* and *E. coli* (enteric colibacillosis) were the most common pathogens and disease was most usually associated with insufficient absorption of colostrum. Coccidiosis and nematodiosis were diagnosed in older lambs and frequently there was a combined infection. Using a forecasting system based on climate data, AFBI Veterinary Sciences Division predicted that hatching of *Nematodirus* eggs would start early in 2022 and that 10 % of the annual hatch would occur between 10th and 22nd of March 2022. Meteorological readings indicated that peak hatching would take place between 27th March and 8th April 2022 and this was borne out by events. Mesenteric torsion associated with over-feeding of grain to early finishing lambs was also seen in several flocks. In some instances the lambs themselves were not being given concentrate feed but were gaining access to ewe rations. Episodes of pneumonic pasteurellosis were seen in growing lambs with intercurrent coccidiosis and / or nematodiosis.

#### Johne's disease

Four sera were tested for MAP antibody during the reporting period, of these one was positive.

Johne's disease was diagnosed in a three-year-old ram which had stopped eating after a period of wasting. The ram was in thin body condition with generalised carcass oedema and on gross examination marked yellowish pigmentation of the ileal mucosa was noted (FIGURE 3). MAP nucleic acid was detected in faeces by RT-PCR and the ram was serologically positive also. There was significant intercurrent parasitic gastroenteritis (PGE) in this case.

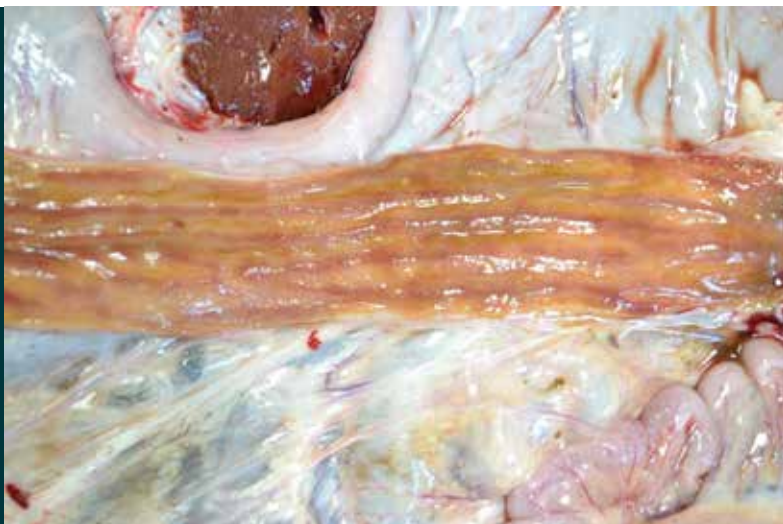


FIGURE 3: Pigmented ileal mucosa, Johne's disease in an adult ram

## Nutritional and metabolic disease

### Goitre in a lamb

Goitre (FIGURE 4) was diagnosed in a 4.5 kg female lamb with an enlarged thyroid (weight: 21.6g) causing a visible swelling in the neck. There was oedema of the neck in the region of the thyroid and also submandibular oedema. There was subcutaneous oedema of the head and the tongue was swollen. Histology showed thyroid follicles lined by tall columnar epithelium, devoid of colloid and containing frequent epithelial invaginations.

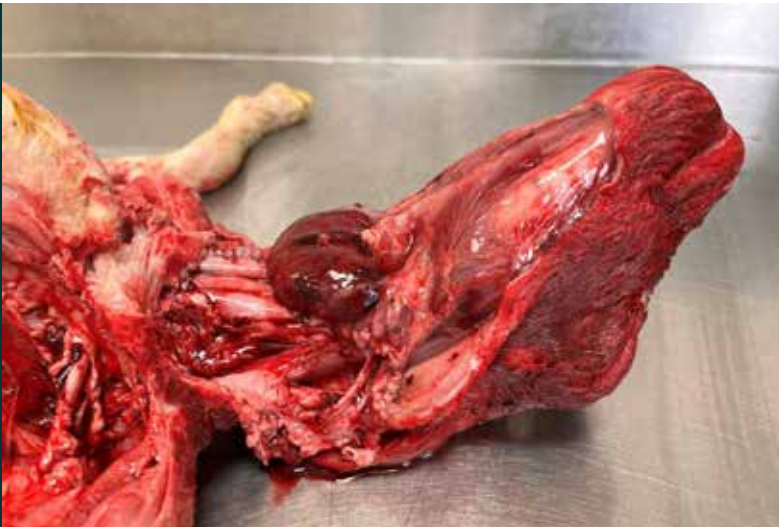

FIGURE 4: Goitre in a lamb, showing the enlarged thyroid gland

## Reproductive diseases

### Abortion

The number of abortion submissions fell markedly during the reporting period compared to the first quarter of the year. Abortion due to *Toxoplasma gondii* was most common during the reporting period.

### Neurological diseases

Cerebrocortical necrosis (CCN) was diagnosed in two one-month-old lambs submitted with a history of stargazing. Histologically, there was multifocal liquefactive necrosis and rarefaction predominantly within the cerebral white matter with focal extension into the gray matter (FIGURE 5), characterized by loss of tissue architecture, scattered cellular debris and oedema.

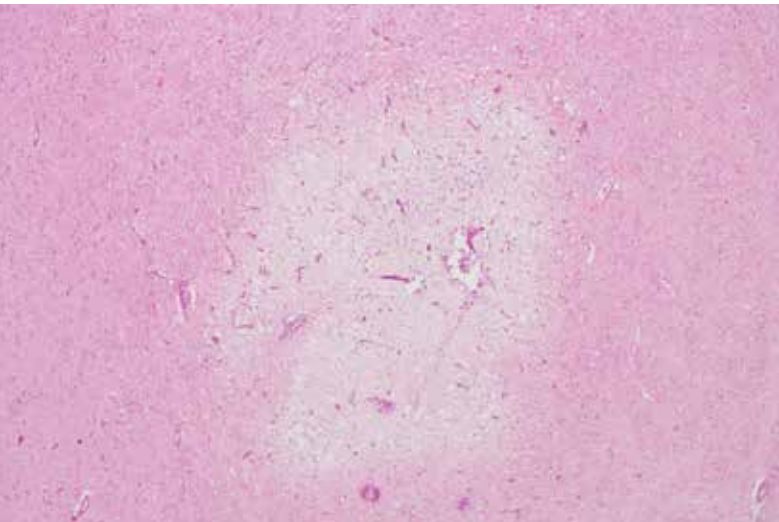


FIGURE 5: CCN in a lamb showing characteristic rarefaction of the white matter

At the periphery of the areas of rarefaction there was spongiosis characterized by vacuolation of the neuropil as well as many dilated axon sheaths with swollen, pale eosinophilic axons. Vessels were congested, lined by hypertrophic endothelial cells, and there was marked expansion of Virchow-Robins space by increased clear space and occasional bright eosinophilic proteinaceous fluid (oedema).

## Other diseases of small ruminants

### Fighting injury in a ram lamb

Fracture of the cranial extremity (the dens) of the second cervical vertebra (the axis) was diagnosed as the cause of death in a four-month-old Suffolk ram lamb. Fighting was considered as a possible cause.

### Enterotoxaemia in a goat

Enterotoxaemia was diagnosed in a three-year-old milking dairy goat. At post mortem examination evidence of enteritis was noted, and on histological examination of the colon, occasional focal loss of mucosa with associated presence of subacute inflammation in the subjacent muscularis mucosae/ submucosa was noted. In the ileum there was colonisation of the superficial mucosa by rod-shaped and filamentous bacteria. The intestine was negative for acid-fast microorganisms by ZN stain, and parasitology was unremarkable. The intestinal content was positive for *Clostridium perfringens* epsilon toxin, and in this case it was considered likely that the cause of death was clostridial enterotoxaemia.

## HORSES:

One swab was examined for the presence of *Streptococcus equi* during the quarter, this was negative.

Fifteen swabs were examined for the presence of *Tayorella equigenitalis* , all were negative.

### Abortion due to EHV-1

Abortion due to Equine Herpes virus (EHV-1) was diagnosed in a one month premature foal. On gross examination there was icterus, an enlarged and congested liver with rounded borders and presence of fluid in the abdominal and thoracic cavities. Foetal liver, lung and adrenal gland were positive for EHV-1 on immunofluorescence.